Veterinary Anaesthesia and Analgesia 2017, **xxx**, 1–8 https://doi.org/10.1016/j.vaa.2017.09.039

RESEARCH PAPER

Development of an ultrasound-guided technique for retrobulbar nerve block in dromedary camels: a cadaveric study

Q1 Q2 Q14

Q13 Q3 **Adel M Badawy & Eman A Eshra**

Department of Veterinary Surgery, Anesthesiology and Radiology, Faculty of Veterinary Medicine, Q4 Benha University, Toukh, Egypt

Correspondence: Adel M Badawy, Department of Veterinary Surgery, Anesthesiology and Radiology, Faculty of Veterinary Medicine, Benha University, Toukh, Qaliobia, 13736, Egypt. E-mail: adelbadawybadawy@yahoo.com

Abstract

Objective Description of an ultrasound (US)-guided technique for retrobulbar nerve blockade in dromedary (*Camelus dromedarius*) cadavers.

Study design Prospective experimental cadaveric study that was carried out in three phases: phase I: anatomical dissection and development of US-guided technique; phase II: methylene blue (MB) injection; phase III: contrast medium (CM), US-guided injections with computed tomography (CT) control.

Animals A total of 36 orbits from 18 heads were obtained from 18 dromedary cadavers.

Methods Phase I: anatomical dissections were carried out bilaterally, using two heads to determine needle site placement. Phase II: a US-guided, lateral, in-plane approach using one of three volumes of MB (3, 6, or 9 mL) was evaluated in six heads (four orbits per volume tested) to establish the ideal injection volume. Injections of MB that strongly stained all retrobulbar nerves were considered successful, whereas insufficient MB volumes resulted in weak or no nerve staining. Phase III: US-guided retrobulbar injection with CM was carried out using 20 orbits. CT was performed after each injection trial to determine the accuracy of needle placement and CM dispersal. An injection was judged to be successful when the CT images revealed that the needle was located within the retractor bulbi muscle cone and the CM reached the target nerves at the orbitorotundum and the optic foramina.

Results Only injection of 9 mL of MB stained the target nerves sufficiently, whereas there was no or only weak staining with 3 and 6 mL, respectively. Therefore, 9 mL of CM was used for the US-guided injections in phase III. Subsequent CT scans revealed satisfying CM distribution within the ocular muscle cone in 18 of 20 cases (90% success rate).

Conclusions and clinical relevance US-guided retrobulbar injection in dromedary cadavers is feasible. Further research is required to assess its practicality and usefulness *in vivo*.

Keywords camel, *Camelus dromedarius*, dromedary, nerve block, orbit, retrobulbar analgesia, sono-anatomy, ultrasonography. Q5

Introduction

Retrobulbar nerve blockade (RNB) is a well-studied and widely accepted technique in large animals that allows eye surgery in nonanaesthetized animals. This reduces the need for general anaesthesia and avoids negative side effects of recumbency and systemic analgesics (Gilger & Davidson 2002). Motor and sensory anaesthesia of the eyeball can be achieved by blockade of the optic, oculomotor, abducent and trochlear nerves and ophthalmic and maxillary branches of trigeminal nerve (Yanoff et al. 2004). Therefore, it is a technique that can be used for many ophthalmic procedures requiring effective ocular anaesthesia and akinesia.

Knowledge of normal anatomy is essential to accurately plan any local anaesthetic technique. However, the available anatomical information including, the topography and internal structure of the dromedary orbit, is incomplete. Additionally, the anatomy of the orbital region in the dromedary differs greatly from that of ruminants and horses (Smuts & Benzuidenhout 1987; Yahaya et al. 2011; Almayahi 2014). For these reasons, the traditional blind RNB techniques

UNCORRECTED PROOF

Please cite this article in press as: Badawy AM, Eshra EA Development of an ultrasound-guided technique for retrobulbar nerve block in dromedary camels: a cadaveric study, Veterinary Anaesthesia and Analgesia (2017), https://doi.org/10.1016/j.vaa.2017.09.039

ARTICLE IN PRESS

commonly used in other large animals are not suitable for dromedaries as they rely solely upon anatomical landmarks to approximate the location of needle placement. Moreover, the orbital dimensions are remarkably small in dromedaries, which may increase the risk of penetration of the eyeball and/or injury of orbital nerves during local anaesthetic injection. Thus, the development of a feasible blind technique for RNB could be challenging in camels and realtime-ultrasound (US) visualization might be a helpful tool.

Ultrasonography provides good visualization of the anatomical details of the eye in relation to the other orbital components (Gayer et al. 2009). Moreover, it allows optimal local anaesthetic deposition through direct visualization of the needle tip during its advancement, which could decrease the incidence of puncture of the eye ball and could help prevent damage to the sensitive orbital structures (Luyet et al. 2008; Morath et al. 2013). US-guided injection is a routine technique for regional analgesic procedures in humans, and is considered the standard of care for administration of local anaesthesia (Sites & Brull 2006; Kapral et al. 2008; Perlas et al. 2008). It has been increasingly used to facilitate blockade of challenging nerves in animals (Shilo et al. 2010; Costa-Farré et al. 2011; Echeverry et al. 2012; Cunha et al. 2013). US-guided techniques for RNB have been studied in horses (Morath et al. 2013), cats (Shilo-Benjamini et al. 2013) and rabbits (Najman et al. 2015).

To the best of the authors' knowledge, US-guided RNB in dromedaries has not been described before, and therefore, this study may provide the first description in this species. The objective of this prospective study was to describe and validate an approach for US- guided, retrobulbar anaesthesia in dromedaries by means of anatomical dissection, methylene blue (MB) injections and computed tomography (CT) studies. The hypothesis of the study was that US guidance would be helpful in identification of important anatomical structures, especially the globe, the muscular cone and the optic nerve, and would allow optimal needle placement within the extraocular muscle cone (intraconal) where all the important nerves can be targeted without damaging the eyeball or the optic nerve.

Materials and methods

Animals

This study was approved by the Institutional Animal Care and Use Committee of Benha University, Egypt. The study included 36 orbits of 18 apparently healthy mature dromedaries (*Camelus dromedarius*) (4–6 years old). The heads were obtained immediately after slaughter and were cooled at 4 °C for an average of 24 hours until US examination was performed. Congenital or acquired abnormalities of the eye or orbital regions were considered exclusion criteria.

Study design

The study was carried out in three phases: anatomical dissection, defining needle placement and development of US-guided technique (phase I); MB injection (phase II); and contrast medium (CM) US-guided injections with CT control (phase III).

Phase I (n = 4): anatomical dissection, definition of needle placement and development of US-guided technique Q15

Two orbits were carefully dissected to identify the target nerves, exit foramina, feasible approach and the site of needle placement. In another two orbits, the needle was inserted prior to dissection using US imaging in order to validate the selected site of needle placement and to determine the ultrasonographic landmarks.

Phase II (n = 12): MB injection

Twelve orbits were used to determine the appropriate volume of injection to achieve the best possible spread around the target nerves, which were considered to be the optic, oculomotor, abducent, trochlear, maxillary nerves and the ophthalmic branch of the trigeminal nerve. Some 3, 6 or 9 mL of MB were injected via US guidance using four orbits to investigate each volume. Subsequently, each orbit was carefully dissected until the target nerves could be identified and the spread of the dye was evaluated. The injection was considered successful when MB solution strongly stained all the target nerves, and failed if weak or no staining was observed.

Phase III (n = 20): CM US-guided injections with CT control

The US-guided RNB technique was carried out in 20 orbits using a US machine (SonoVet R3; Samsung Medison Co., Korea) with a convex transducer, scan width of 20–22 mm, 4–9 MHz (CN4; Samsung Medison Co.). All examinations and injection trials were carried out by the same operator (AMB). The

© 2017 Association of Veterinary Anaesthetists and American College of Veterinary Anesthesia and Analgesia. Published by Elsevier Ltd. All rights reserved., ■, 1–8

Please cite this article in press as: Badawy AM, Eshra EA Development of an ultrasound-guided technique for retrobulbar nerve block in dromedary camels: a cadaveric study, Veterinary Anaesthesia and Analgesia (2017), https://doi.org/10.1016/j.vaa.2017.09.039

investigator had significant clinical experience in US examinations.

Prior to US examination, each eyeball was injected with saline (0.9 % NaCl) using a 22 gauge needle, until the eyeball felt plump on palpation, to restore physiologic ocular pressure and globe size. Thereafter, the US probe was positioned horizontally on the closed eyelid to visualize the eyeball, extraocular muscle cone and the optic nerve. A 21 gauge × 80 mm needle was inserted in-plane in relation to the probe, just caudal to the junction between the caudal border of zygomatic process of the frontal bone and the zygomatic arch (Fig. 1a and b). From this position, the needle was advanced under US guidance in a horizontal and slightly ventral direction, until the tip of the needle was positioned in the caudal part of the muscular cone (intraconal position). A CT scan was then performed to determine the position of the needle (intraconal or extraconal). On CT images, the needle depth and distance between the needle tip and the optic nerve were determined. The needle depth was determined as the distance between the site of needle insertion (skin surface) and the needle tip. The CT scans were carried out with tube setting of 110 kV, 160 mA and 0.75 mm collimation by using a 64 detector row CT scanner (Somatom Sensation; Siemens Medical Solutions, Germany). Each head was placed in the gantry in the horizontal position, parallel to the CT couch, simulating head direction in living animals. All CT images were reformatted in coronal, sagittal and transverse planes with a slice thickness of 1 mm in increments of 0.6, using a soft tissue window [window width (WW) = 280, window level (WL) = 120 Hounsfield unit (HU)] and a bone window (WW = 3200 HU,WL = 700 HU). The reformatted images were analysed using commercially available image analysis software (Syngo CT 2006G, ICS VB28B; Siemens, Germany).

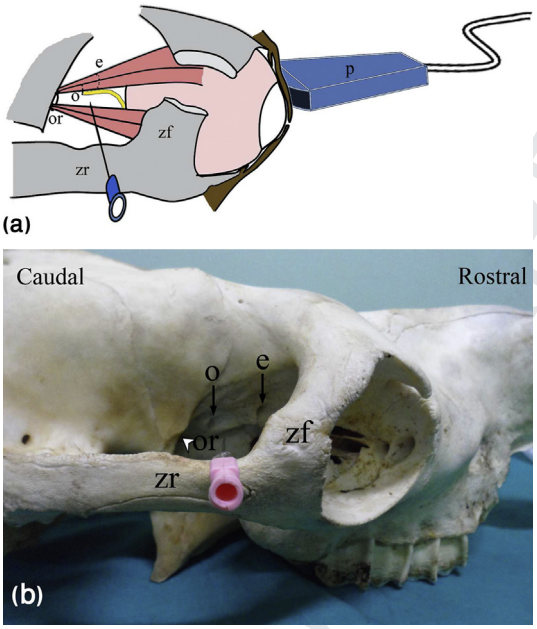

Figure 1 (a) An illustration of the dromedary orbit demonstrating the technique for retrobulbar injection; (b) side view of dromedary skull showing the site of needle insertion. e, ethmoidal foramen; o, optic foramen; or, orbitorotundum foramen; p, ultrasound probe; zf, zygomatic process of frontal bone; zr, zygomatic arch.

Subsequently, a CM (Ioversol Optiray 300; Mallinckrodt Inc., MO, USA) diluted 1:1 with normal saline to a total volume of 9 mL was injected in each orbit under US-visualization and the spread of the CM was observed.

Finally, each head was subjected to CT scans to confirm dispersal of the CM. The injection trial was considered to be successful when the needle was confirmed to be intraconal and the CM reached the site of target nerves at the orbitorotundum and optic foramina on the CT images. If the needle was located outside the muscular cone (extraconal) and/or the CM did not reach the exit sites of the target nerves, the injection trial was considered unsuccessful.

Statistical analysis Q6

The statistical procedures in this study were performed using a commercially available software program (SPSS, Version 16.0; SPSS Inc., IL, USA). Data of CT measurements described in phase III were evaluated for normality using the Shapiro-Wilk test, and the data were determined to be normally distributed and are presented as mean ± standard deviation. Q7

Results

Phase I ($n = 4$): anatomical dissection, defining needle placement and development of US-guided technique

The dromedary bony orbital rim is complete. The prominent dorsal and caudal bony boundaries are formed by the zygomatic processes of the frontal and temporal bones, respectively (Figs 1b and 2). The main arteries and veins parallel each other, medially in the orbit. All the nerves of the eye run along the inside of the muscle cone (intraconal). They include the optic, oculomotor, abducent, trochlear, maxillary

© 2017 Association of Veterinary Anaesthetists and American College of Veterinary Anesthesia and Analgesia. Published by Elsevier Ltd. All rights reserved.,

Please cite this article in press as: Badawy AM, Eshra EA Development of an ultrasound-guided technique for retrobulbar nerve block in dromedary camels: a cadaveric study, Veterinary Anaesthesia and Analgesia (2017), https://doi.org/10.1016/j.vaa.2017.09.039

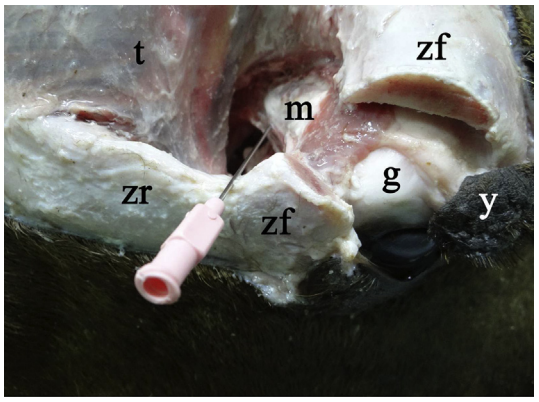

Figure 2 Side view of the camel orbit; the skin was reflected and the periorbital fat was completely removed. The zygomatic process of the frontal bone was partly incised showing the eye globe (g), muscle cone (m), temporal muscle (t), zygomatic process of frontal bone (zf), zygomatic arch (zr) and upper eyelid (y). Note that the needle was inserted just caudal to the junction between the zygomatic process of frontal bone (partly cut) and the zygomatic arch.

nerves and the ophthalmic branch of the trigeminal nerve. All nerves except the optic nerve exit the skull through the orbitorotundum foramen (ORF), which is the largest foramen at the most caudo-distal limit of the orbit (Fig. 2). The optic nerve enters the orbit through the optic foramen which is located anterior and slightly dorsal to the ORF; the optic canal and its foramen have clearly defined raised edges (Fig. 2).

The lateral approach was selected for the US-guided injection. The probe was positioned horizontally on the closed upper eyelid. Within the US field of view, the eyeball was a rounded hypoechoic structure that was surrounded by a hyperechoic extra-ocular cone of muscles. The optic nerve was better visualized when the probe was rotated clockwise to an angle of 10° from the horizontal plane and was recognized as a longitudinal hypoechoic area inside the muscle cone. The needle tip was visualized simultaneously with the optic nerve by rotating the probe clockwise to an angle of 20–25° relative to the horizontal plane.

The optimum site of needle placement was directly caudal to the bony orbit, at the junction between the caudal border of zygomatic process of the frontal bone and the dorsal border of the zygomatic arch. To achieve intraconal injection, the needle was advanced under US guidance in a horizontal direction, and slightly ventral, through the caudal part of muscular cone, parallel to a line joining the two lateral canthi.

Phase II ($n = 12$): MB injection

MB injections were carried out in 12 orbits under US guidance using the lateral approach. Using a volume of 3 mL of MB, the staining of target nerves was weak (two of four cases) or unstained (two of four cases), whereas with a volume of 6 mL, the nerves were completely stained in three of four cases, and incompletely stained in only one of four cases. Using volumes of 9 mL, all target nerves were strongly stained (four of four cases), and no excessive spreading of the dye was detected (Fig. 3). Consequently, volumes of 3 and 6 mL of MB were considered inadequate. The technique was, however, considered successful when using a volume of 9 mL of MB and this volume was then used for the third phase of the study.

Phase III ($n = 20$): CM US-guided injections with CT control

The US-guided retrobulbar injections with 9 mL CM were performed in 20 orbits using the technique developed in phase I. In 16 of 20 cases the different orbital structures, in particular the eye globe, the muscular cone and the optic nerve, were well defined on US images and the needle position was easily visualized (Fig. 4a). In four cases, the anatomical structures

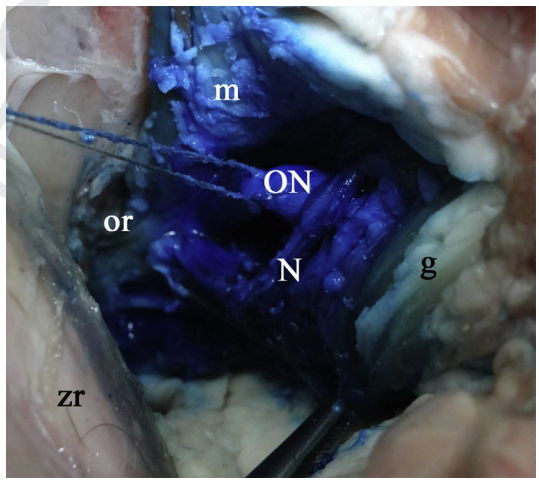

Figure 3 Appearance of the dissected target retrobulbar nerves in a dromedary orbit, caudal to the globe (g). Nerves were stained with 9 mL of 1.4% methylene blue using the lateral retrobulbar approach. All anatomical structures medial to the zygomatic arch (zr) were removed and the muscle cone (m) was opened. Note that all target nerves, including the optic nerve (ON; tied with a string) and the retrobulbar nerves (N) were coloured deep blue. Also note that the optic nerve exit is dorsal and slightly rostral to the orbitorotundum foramen (or).

© 2017 Association of Veterinary Anaesthetists and American College of Veterinary Anesthesia and Analgesia. Published by Elsevier Ltd. All rights reserved.,

UNCORRECTED PROOF

Please cite this article in press as: Badawy AM, Eshra EA Development of an ultrasound-guided technique for retrobulbar nerve block in dromedary camels: a cadaveric study, Veterinary Anaesthesia and Analgesia (2017), https://doi.org/10.1016/j.vaa.2017.09.039

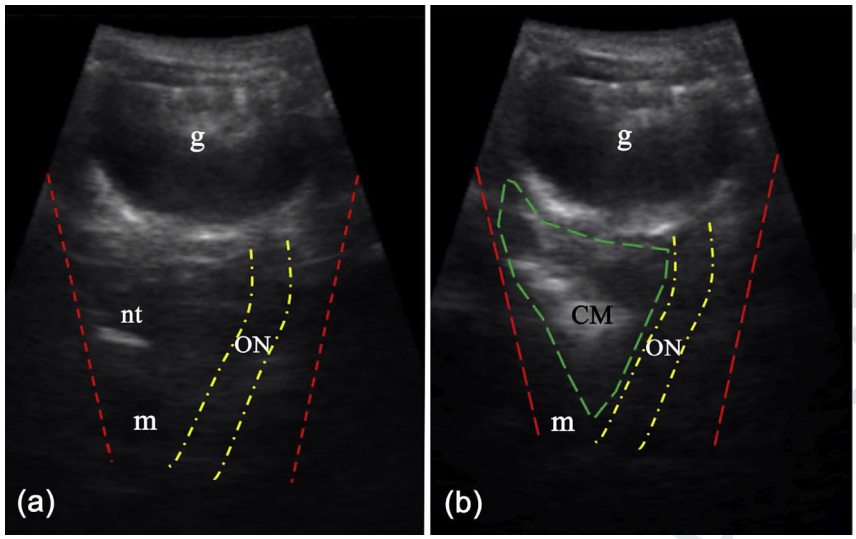

Figure 4 Ultrasound images of a dromedary orbit (a) before and (b) after needle insertion, showing the globe (g), the muscle cone (m), the optic nerve (ON), the contrast medium (CM) and the needle tip (nt).

were easily defined on US images, but visualization of the placement of the needle tip was difficult. The spread of the contrast dye during the injection was easily observed in all cases. The CM appeared as an extending hyperechoic area that reached the caudal limit of the orbit in all cases (Fig. 4b).

The CT scans of the aforementioned 16 cases confirmed that the needle was in the muscle cone (intraconal) and CM reached the target foramina (Fig. 5a and b). In the four cases where the US visualization of needle was impaired, the CT scans demonstrated an intraconal needle position in two cases and extraconal in the other two cases. The CM reached the exit of the target nerves in the two intraconal cases, and was located between the medial wall of the orbit and muscle cone in the two extraconal cases. Consequently, the injection was judged as successful in 18 of 20 cases (90% success rate). These were the cases in which the needle was positioned intraconally and the CM reached the target foramina (orbitorotundum and optic foramina). In these successful cases, the CT images showed a homogenous distribution of radiopaque CM within the muscular cone (Fig. 5b). The needle depth was 63.31 ± 0.36 mm, and the distance between the needle tip and the optic nerve was 5.24 ± 0.35 mm.

Discussion

US-guided injection for RNB with 9 mL of CM proved to be a feasible and reproducible technique using a lateral in-plane approach in dromedary cadaver orbits, as demonstrated by the anatomical, ultrasonographic and CT studies. Moreover, the MB injections were successful when using a volume of 9 mL of MB, whereas volumes of 3 and 6 mL were inadequate. Damage to major intraorbital structures with the inserted needle was assumed to be prevented since no case of inadvertent puncturing was recorded by the CT scans. All but two attempts resulted in sufficient distribution of CM towards the bony outlets of the target nerves. In these two cases, the CM was located extraconally and did not reach the targeted foramina. In live animals, nerves that run outside the muscle cone would also be blocked. The unsuccessful attempts may have been caused by poor visualization of the orbital structure and the needle position on US images. Using needle enhancing software that intensifies the brightness of the needle during US-guided procedures may eliminate the problem of poor needle visualization (Viscasillas et al. 2013) and increase the success rate of this technique.

Although the lateral approach is not common, the anatomical study revealed that it would be the technique of choice, because it allowed the needle to be inserted away from the vital orbital structures, including the eyeball, the optic nerve and the major blood vessels. This consequently diminishes the possibility of globe penetration, injury of the optic nerve and intravascular injection.

In horses, the dorsal approach is feasible because of the presence of a deep temporal fossa (Gilger &

© 2017 Association of Veterinary Anaesthetists and American College of Veterinary Anesthesia and Analgesia. Published by Elsevier Ltd. All rights reserved.,

Please cite this article in press as: Badawy AM, Eshra EA Development of an ultrasound-guided technique for retrobulbar nerve block in dromedary camels: a cadaveric study, Veterinary Anaesthesia and Analgesia (2017), https://doi.org/10.1016/j.vaa.2017.09.039

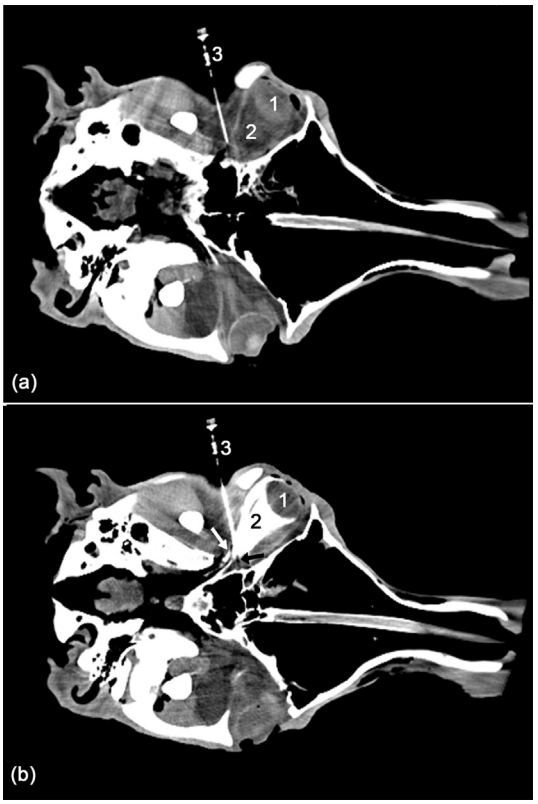

Figure 5 (a) Reformatted, coronal plane computed tomography image of a dromedary cadaver head before the injection of contrast medium injection, showing the intraconal position of the needle; (b) post contrast computed tomography (CT) image, showing the dispersion of contrast medium (CM) inside the muscular cone. 1, eyeball; 2, muscle cone; 3, needle; white arrow, the orbitorotundum foramen; black arrow, optic foramen.

Davidson 2002; Morath et al. 2013). In dromedaries, there is also a temporal fossa (Smuts & Benzuidenhout, 1987), which may allow the dorsal approach to be conducted in this species; however, the lateral approach used in this study allowed deposition of CM almost directly onto the nerves, leaving a safe distance between the optic nerve and the needle tip. In contrast, the dorsal approach has the disadvantage of being closer to the caudal part of eye globe and its surrounding structures, which may increase the possibility of eyeball and optic nerve sheath penetration. However, further studies are needed to compare clinical use of both approaches *in vivo*.

Furthermore, retrobulbar anaesthesia in the horses is used to block the orbital nerves exiting the skull through the optic, orbital and round foramina, which are located at the same level and perpendicular to each other in the orbital fissure (Gilger & Davidson 2002; Morath et al. 2013). In dromedaries, however, there is no orbital fissure and only a large ORF is present, through which the nerves of the eye enter the orbit. These nerves include the oculomotor, abducent, trochlear, maxillary nerves and ophthalmic branch of the trigeminal nerve (Smuts & Benzuidenhout 1987). The optic nerve exits separately from the optic canal, which is located higher and slightly anterior to the ORF. The locations of the ORF as well as the optic canal were easily identified on CT images, which facilitated assessment of the success rate of the technique.

Several parameters are important for development of a new US-guided nerve block technique, including probe selection, ultrasonographic landmarks (acoustic windows) and the final approach. The US-guided injections in dromedaries were challenging and the orbital configuration limited the acoustic windows. Using a 4−9 MHz convex probe on the closed upper eyelid provided better resolution and penetrated to a sufficient depth. Two US approaches can be used any anaesthetic technique: the in-plane or the out-of-plane approach. The needle is best identifiable using the in-plane approach and typically appears as one long line, while the out-of-plane approach allows only the needle tip to be visualized as a small bright dot (Reusz et al, 2014). However, the lateral, in-plane approach used in this study was carried out with the needle inserted away from the probe, which allowed simultaneous visualization of the eyeball, the muscular cone and the optic nerve, and permitted tracking of the needle tip in real-time and avoided a closer entry point, which is more likely to expose the eyeball to needle-injuries and globe penetration.

CT is a standard method for testing accuracy of US-guided injections (Adami et al. 2013; Morath et al. 2013; Shilo-Benjamini et al. 2013). The CT scans provide simultaneous visualization of both the hard and soft tissues and it is possible to recreate three dimensional and transverse images in several planes (Morrow et al. 2000; Tucker & Sande 2001). In this study, CT scans were helpful to identify the orbital bony structures, in particular the exit of target nerves and essential soft tissue structures, such as the eyeball and muscular cone. It was also beneficial in detection of the needle position, as well as CM distribution.

Several complications may be associated with retrobulbar injection including, retrobulbar haemorrhage, puncture of the eye globe or optic nerve sheath (Grizzard et al. 1991; Thurmon et al. 1996) and intravascular injection of local anaesthetic (Healy & Knight 2003; Dettoraki et al. 2015). We postulate

© 2017 Association of Veterinary Anaesthetists and American College of Veterinary Anesthesia and Analgesia. Published by Elsevier Ltd. All rights reserved.,

Please cite this article in press as: Badawy AM, Eshra EA Development of an ultrasound-guided technique for retrobulbar nerve block in dromedary camels: a cadaveric study, Veterinary Anaesthesia and Analgesia (2017), https://doi.org/10.1016/j.vaa.2017.09.039

ARTICLE IN PRESS

that such complications would be minimal with use of this technique.

Limitations of this study include the use of only cadaver specimens and the small number of cases (36 orbits). Because this was a study in dromedaries with no detected orbital injuries, the effects of eye abnormalities in live dromedaries remain unknown. To obtain a distribution pattern similar to that of the local anaesthetic solution, the CM solution was diluted 1:1. However, the anaesthetic solution may have a different spreading pattern in the living body, especially when considering the body temperature and the arterial pulsations, which might lead to the spread of 9 mL CM more caudal than the orbitorotundum. Additional studies are required to determine the feasibility of this approach in live and conscious animals including the spreading pattern of 9 mL of undiluted local anaesthetic, the onset and duration of the nerve block and the possible post-anaesthetic complications. Further studies are also recommended to determine whether this technique is easier to learn than the blind technique, using this new, lateral, in-plane approach. Nonetheless, the results of the present study show that US-guided RNB could be clinically useful in dromedaries.

In conclusion, this study demonstrates the feasibility of US- guided injection for RNB using 9 mL of CM in dromedary cadavers. However, the clinical feasibility of this technique requires evaluation in living dromedaries. Q8

Source of funding

Authors covered the full cost for this work.

Authors' contributions

AMB and EAE: study design, data management, data interpretation and preparation of manuscript. AMB: ultrasound examinations, injection trials and CT interpretations. EAE: anatomical investigations.

Conflict of interest statement

Authors declare no conflict of interest.

References

Adami C, Angeli G, Haenssgen K et al. (2013) Development of an ultrasound-guided technique for pudendal nerve block in cat cadavers. J Feline Med Surg 15, 901–907.

Almayahi MS (2014) Anatomical description of orbital region in one humped camel (*Camelus dramadarius*). Basra J Vet Res 1, 43–49.

Costa-Farré C, Blanch XS, Cruz JI et al. (2011) Ultrasound guidance for the performance of sciatic and saphenous nerve blocks in dogs. Vet J 187, 221–224.

Cunha AF, Strain GM, Rademacher N et al. (2013) Palpation and ultrasound-guided brachial plexus blockade in Hispaniolan Amazon parrots (*Amazona ventralis*). Vet Anaesth Analg 40, 96–102. Q9

Dettoraki M, Dimitropoulou C, Nomikarios N et al. (2015) Generalized seizures and transient contralateral hemiparesis following retrobulbar anesthesia: a case report. BMC Anesthesiol 15, 108.

Echeverry DF, Laredo FG, Gil F et al. (2012) Ultrasound-guided 'two-in-one' femoral and obturator nerve block in the dog: an anatomical study. Vet Anaesth Analg 39, 611–617.

Gayer S, Palte H, Kumar C (2009) Real-time visualization of ultrasound-guided retrobulbar visualization of ultrasound-guided retrobulbar blockade: an imaging study. Br J Anaesth 102, 561–562.

Gilger BC, Davidson MG (2002) How to prepare for ocular surgery in the standing horse. In: Proceedings of the 48th Annual Convention of the American Association of Equine Practitioners, FL, Orlando. pp. 266–271. Q10

Grizzard WS, Kirk NM, Pavan PR et al. (1991) Perforating ocular injuries caused by anesthesia personnel. Ophthalmology 98, 1011–1016.

Healy TEJ, Knight PR (2003) Wylie Churchill-Davidson's A Practice of Anesthesia (7th edn). CRC Press. Q11

Kapral S, Greher M, Huber G et al. (2008) Ultrasonographic guidance improves the success rate of interscalene brachial plexus blockade. Reg Anesth Pain Med 33, 253–258.

Luyet C, Eichenberger U, Moriggl B et al. (2008) Real-time visualization of ultrasound-guided retrobulbar blockade: an imaging study. Br J Anaesth 101, 855–859.

Morath U, Luyet C, Spadavecchia C et al. (2013) Ultrasound-guided retrobulbar nerve block in horses: a cadaveric study. Vet Anaesth Analg 40, 205–211.

Morrow KL, Park RD, Spurgeon TL et al. (2000) Computed tomographic imaging of the equine head. Vet Radiol Ultrasound 41, 491–497.

Najman IE, Ferreira JZ, Abimussi CJX et al. (2015) Ultrasound-assisted periconal ocular blockade in rabbits. Vet Anaesth Analg 42, 433–441.

Perlas A, Brull R, Chan VWS et al. (2008) Ultrasound guidance improves the success of sciatic nerve block at the popliteal fossa. Reg Anesth Pain Med 33, 259–265.

Reusz G, Sarkany P, Gal J et al. (2014) Needle-related ultrasound artifacts and their importance in anesthetic practice. Br J Anaesth 112, 794–802.

Shilo Y, Pascoe PJ, Cissell D et al. (2010) Ultrasound-guided nerve blocks of the pelvic limb in dogs. Vet Anaesth Analg 37, 460–470.

© 2017 Association of Veterinary Anaesthetists and American College of Veterinary Anesthesia and Analgesia. Published by Elsevier Ltd. All rights reserved., ■, 1–8

Please cite this article in press as: Badawy AM, Eshra EA Development of an ultrasound-guided technique for retrobulbar nerve block in dromedary camels: a cadaveric study, Veterinary Anaesthesia and Analgesia (2017), https://doi.org/10.1016/j.vaa.2017.09.039

UNCORRECTED PROOF

ARTICLE IN PRESS

Shilo-Benjamini Y, Pascoe PJ, Maggs DJ et al. (2013) Retrobulbar and peribulbar regional techniques in cats: a preliminary study in cadavers. Vet Anaesth Analg 40, 623–631.

Sites BD, Brull R (2006) Ultrasound guidance in peripheral regional anesthesia: philosophy, evidence-based medicine, and techniques. Curr Opin Anaesthesiol 19, 630–639.

Smuts MW, Benzuidenhout AJ (1987) Anatomy of the Dromedary. Clavendon Press, Oxford, USA.

Thurmon JC, Tranquilli WJ, Benson GJ (1996) Local and regional anaesthetic techniques: ruminants and swine. In: Lumb and Jones Veterinary Anaesthesia (3rd edn). Lippincott Williams and Wilkins, Philadelphia. pp. 183–209.

Tucker RL, Sande RD (2001) Computed tomography and magnetic resonance imaging of equine musculoskeletal conditions. Vet Clin North Am Equine Pract 17, 145–157.

Viscasillas J, Benigni L, Brodbelt D et al. (2013) Use of needle enhancing software to improve injection technique amongst inexperienced anaesthetists performing ultrasound-guided peripheral nerves blocks in dogs. Vet Anaesth Analg 40, 83–90.

Yahaya A, Olopade JO, Kwari HD (2011) Clinical implications of craniometric indices of the one-humped camel (*Camelus dromedarius*) to oral health and clinical regional anaesthesia of the head. J Vet Anatomy 4, 19–31.

Yanoff M, Duker JS, Augsburger JJ et al. (2004) Ophthalmology (3rd edn). Mosby, St. Louis, MO. pp. 441–446. Q12

Received 12 April 2017; accepted 26 September 2017.

Available online xxx

UNCORRECTED PROOF

© 2017 Association of Veterinary Anaesthetists and American College of Veterinary Anesthesia and Analgesia. Published by Elsevier Ltd. All rights reserved., ■, 1–8

Please cite this article in press as: Badawy AM, Eshra EA Development of an ultrasound-guided technique for retrobulbar nerve block in dromedary camels: a cadaveric study, Veterinary Anaesthesia and Analgesia (2017), https://doi.org/10.1016/j.vaa.2017.09.039